

Second-Degree AV Block

Ross MacKenzie, MD

Second-degree AV block includes a variety of conduction patterns of variable prognostic significance. Careful analysis of the pattern of PR and R-R intervals, the QRS axis and duration, as well as the presence or absence of structural heart disease should allow the medical director to assess the applicant's risk for life insurance.

Address: Ross MacKenzie Consulting, 2261 Constance Drive, Oakville, Ontario, L6J 5L8, Canada; e-mail: rossmackenzieconsulting@msn.com.

Correspondent: Ross MacKenzie, MD, FRCP(C), FACC

Key words: Electrocardiography prognosis, differential diagnosis, second-degree AV block, Mobitz type I and II block, Wenckebach phenomenon.

Received/Accepted: September 20, 2004

CASE SCENARIO

A 50-year-old male geologist is applying for a universal life insurance policy. His past health is unremarkable. He is a nonsmoker, and there is no history of hypertension or hyperlipidemia. He has no symptoms at present and is physically active, curling and skiing in the winter and sailing in the summer. Both parents died in their early 70s. His father had a permanent pacemaker and died from prostate cancer. His mother died from a pulmonary embolus following a hip fracture.

The applicant has spent much of his career working on projects in the remote tropical regions of Africa, Asia and South America. He recalls experiencing a variety of brief febrile illnesses, which responded to symptomatic treatment. He has never had malaria or Chagas disease (trypanosomiasis).

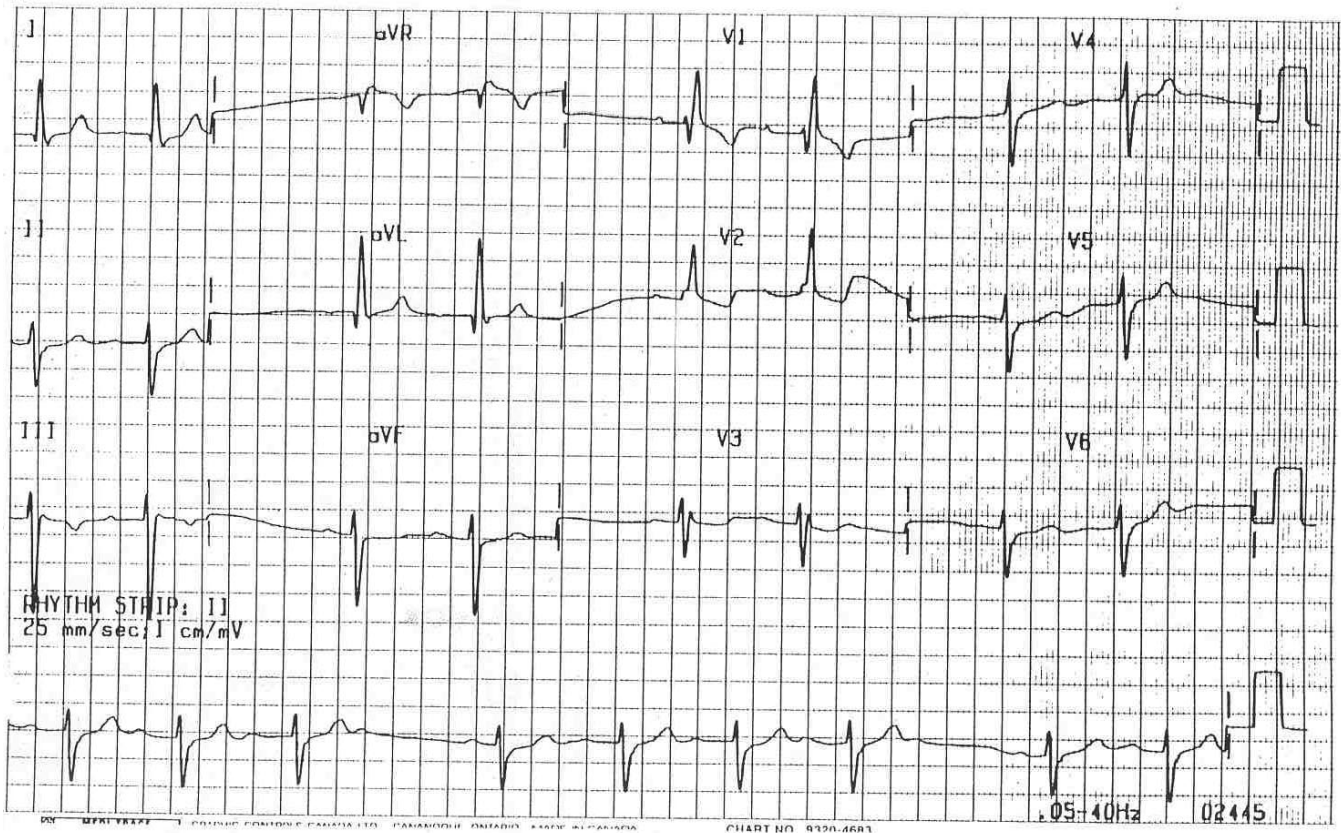
He is 6 ft tall and weighs 205 lb. Physical

examination is normal. Blood pressure is 138/84. Routine blood work and urinalysis are normal.

The Figure is the electrocardiogram (ECG) obtained for age and amount at the time of application. Is it normal or abnormal? If it is abnormal, what is the principal abnormality? Could this abnormality be a normal variant? If there is an abnormality how does it affect your mortality assessment in this case?

ECG INTERPRETATION

The prevailing rhythm is sinus in origin at rates of about 70 times a minute. The tracing is abnormal and is of interest for several reasons. First, there is an irregularity of the rhythm with the cardiac cycles occurring in groups of 2, 3 or 4 complexes best illustrated at the bottom of the tracing in the rhythm strip. This is called "group beating" and the



Applicant's electrocardiogram.

reasons for its presence and its risk assessment implications will be the focus of this article. Second, the mean QRS axis in the frontal plane is markedly deviated to the left and superiorly (approximately -50 degrees). Third, the QRS complexes are widened (0.13 second) and display a pattern of complete right bundle branch block (CRBBB). Last, there are nonspecific ST-T wave changes in leads V_1 - V_3 .

ECG ANALYSIS

We shall first turn our attention to the irregular rhythm. As noted above, the cardiac cycles are occurring in groups separated by pauses. There is a constant appearance of upright P waves (presumably sinus in origin) at a rate of 70 times a minute. Every QRS complex is preceded by a P wave, but not every P wave is accompanied by a QRS complex. Careful examination of the tracing reveals that each pause is associated with a nonconducted P wave. For example, in the rhythm strip at the bottom of the tracing, the first 3

QRS complexes are preceded by sinus P waves. The fourth P wave in this sequence is not followed by a QRS complex and is associated with a pause, which is interrupted by a sequence of 4 P waves associated with QRS complexes that ends with a nonconducted P wave and another pause.

This phenomenon of intermittent failure of some sinus impulses to cross the atrioventricular (AV) junction and bundle of His to depolarize the ventricular myocardium raises two diagnostic possibilities: nonconducted atrial premature beats and second-degree AV block. To differentiate between these two arrhythmias, further analysis of the tracing is necessary.

The first possibility can be assessed readily by observing the morphology of the nonconducted P waves and by assessing their timing. The blocked P waves in our applicant's tracing are similar in morphology and polarity to the sinus P waves. The timing of the P waves can be checked crudely by using a pencil and paper or more precisely by using cal-

ipers. By setting one leg of a pair of calipers on the blocked P wave and the other on the conducted sinus P wave of the next cycle, the distance between the two legs of the caliper defines the P-P interval of the basic sinus rate of about 70 per minute. By keeping this interval constant and moving the caliper back and forth along the tracing, it is clear that the P-P intervals are constant and equal. These findings argue against the possibility that the observed pauses and the blocked P waves are due to nonconducted premature atrial beats.

Our analysis so far has ruled out nonconducted atrial premature beats, identified the nonconducted P waves as sinus P waves, and points towards second-degree AV block as the cause of the irregular rhythm. The ECG hallmark of second-degree AV block is the intermittent failure of sinus beats to reach the ventricles. Four categories of second-degree AV block are generally recognized: Mobitz type I (Wenckebach) and type II block, 2:1 AV block, and advanced AV block.¹ The distinction between the different types of second-degree block is important to the medical director because of their different risk selection implications. Even a casual glance at the tracing shown can establish the absence of persistent 2:1 and advanced AV block. Therefore, the distinction here is between Mobitz types I and II AV Block.

Although the sinus cycles (P-P intervals) in our applicant's tracing are regular and constant, the PR intervals are not. They vary throughout the tracing. For example, in the rhythm strip at the bottom of the tracing, the first PR interval is prolonged. The second PR interval is longer than the first, the third is longer than the second, and the fourth is not conducted. A similar sequence follows the pause until the fifth P wave is not conducted. The observed progressive prolongation of the PR interval that occurs before a P wave is not conducted is characteristic of the Wenckebach phenomenon as seen in Mobitz type I, second-degree AV block.

This diagnosis is supported by several additional ECG findings. First, coincident with the progressive prolongation of the PR inter-

vals, the R-R intervals shorten progressively before the P wave is blocked. This "paradoxical" shortening of the R-R intervals results in a progressive "acceleration" of the ventricular rate and occurs because the increments by which the PR intervals lengthen are progressively shorter until the P wave is blocked. Second, the pauses associated with nonconducted P waves are less than twice the sinus cycle length. Last, R-R intervals that follow pauses are longer than R-R intervals that immediately precede the pauses. These findings are not present in Mobitz type II block.

QRS complexes in Mobitz type I block are usually narrow because the site of the antegrade block is in the AV junction region. Wide QRS complexes may be found; however, when there is a pre-existing bundle branch block or the site of the block is more distal in the conducting system.

Our applicant's tracing does exhibit a number of the features of *classic* Mobitz type I AV block. However, the pattern in many patients will be atypical with one or more features of the Wenckebach phenomenon missing or the associated QRS is wide.^{2,3}

Mobitz type II block also results in nonconducted sinus P waves. In Mobitz type II block, the PR intervals remain constant and the R-R intervals do not shorten before the P wave is blocked. Also, in contrast to Mobitz type I block, wide QRS complexes are usually present because the block is due to disease in the distal intraventricular conducting system.¹

When there is constant 2:1 AV block, every other sinus P wave is blocked. In this setting, type I cannot be differentiated from type II, as there are no series of consecutive PR intervals that can be used to decide whether the intervals lengthen progressively or remain constant before the blocked P wave. Long rhythm strips or continuous monitoring may disclose the transient appearance of other Wenckebach AV ratios (3:2, 4:3, etc), which allow the diagnosis of Mobitz type I AV block. The distinction may also be inferred (but not confirmed) if the width of the QRS complex is examined. A narrow QRS favors type I AV block, and a wide QRS favors type II.⁴ Ad-

vanced second-degree AV block is said to be present when two or more consecutive P waves are blocked.⁴

Several other features of this tracing are worthy of notation because of their prognostic implications. The QRS complexes are broad and display abnormal left axis deviation. The broad QRS complexes display an *rsR'* pattern in precordial lead V_1 , a slurred upstroke in V_2 , and an *rSr'* pattern in V_3 , as well as slurred S waves in I , V_5 and V_6 . The pattern of the QRS complexes resembles that of complete right bundle branch block (CRBBB) but is not entirely classic as there are *rS* patterns in V_4 - V_6 . ST depression is present in V_1 - V_3 with negative or biphasic T waves. These ST-T changes are to be expected in RBBB and are called secondary ST-T changes. It is important not to attribute these secondary ST-T changes (when restricted to these leads) to ischemia or any other clinical disorder.

The presence of abnormal left axis deviation (in the absence of other causes) suggests the presence of left anterior fascicular block (left anterior hemiblock). RBBB by itself does not alter the electrical axis of the QRS complex in the frontal plane.⁵ Therefore, axis deviation, either to the left or the right, suggests concomitant conduction block in the left anterior or left posterior fascicle of the left bundle branch, respectively. Such patterns indicate more extensive involvement of the distal conducting system and are termed collectively as *bilateral* (right and left) bundle branch block and, more specifically, *bifascicular* block.⁵

In the presence of bifascicular block, the additional finding of second-degree AV block further expands the prognostic implications of our applicant's ECG. When intraventricular conduction is normal, AV block usually indicates conduction delay in the AV junctional tissues of the heart. In contrast, when bifascicular block (RBBB + LAFB) is present, AV conduction delay is a less reliable indicator of the site of the delay and may suggest jeopardized conduction in the last remaining third fascicle, the posterior branch of the left bundle branch. This suggests a high-risk sit-

uation much more serious than uncomplicated Mobitz type I AV block.

DISCUSSION

Karel Frederick Wenckebach of Utrecht, the Netherlands, first described type I second-degree AV block in humans in his 1899 paper "On the analysis of irregular pulses." The centennial of this clinical landmark was celebrated in 1999. Although Wenckebach (Venky to his colleagues⁶) called this process "Luciani periods" after the Italian physiologist who observed this phenomenon of group beating in the frog heart in 1872, this pattern is now widely known as the Wenckebach phenomenon and is one of the most famous eponyms in medicine. This discovery was made by simple observation of the pulses in the neck before the introduction of electrocardiography by Willem Einthoven in 1901. In 1906, Wenckebach, then in Vienna and John Hay from Liverpool, England, both described a second form of AV block in which there was no progressive lengthening of the conduction time before conduction failed. In 1924, Mobitz correlated these earlier clinical findings with those in the electrocardiogram and suggested that the first type be called "type I" and the second "type II."^{3,6,7}

Since these historical descriptions, there have been many advances in our understanding of cardiac electrophysiology. Despite this, a great deal of misconception persists about second-degree AV block related to its definitions, site of block and prognostic significance.

The term second-degree AV block is applied when one or more (but not all) sinus impulses that should be conducted fail to reach the ventricles. This term thus covers a variety of conduction patterns of variable prognostic significance. Type I and II block are ECG patterns that describe the behavior of PR intervals (in sinus rhythm) in sequences (with at least two consecutively conducted PR intervals) in which a single sinus P wave fails to conduct to the ventricles.³

Type I block is the occurrence of a single

nonconducted sinus P wave associated with inconstant PR intervals before and after the blocked impulse as long as there are at least two consecutive sinus P waves (ie, 3:2 AV block) to determine the behavior of the PR intervals. The term inconstant PR intervals is important because many type I sequences are atypical and do not conform to the traditional mathematical structure of the Wenckebach phenomenon associated with progression of the PR intervals.^{3,8}

Type I block with a narrow QRS is almost always due to a lesion in the AV node because type I block in the His bundle is rare. In type I block with a wide QRS complex, the block is AV nodal in 30%–40% of cases and is in the His-Purkinje system in 60%–70% of cases. Type I infranodal block indicates diffuse disease of the His-Purkinje system, and its prognosis is believed to be the same as for type II AV block.³

Type II second-degree AV block is defined as the occurrence of a single nonconducted P wave associated with constant PR intervals before and after a single blocked impulse, as long as the sinus rate or P-P interval is constant and there are at least two consecutively conducted P waves (ie, 3:2 AV block) to determine the behavior of the PR interval. The pause encompassing the blocked P wave must be equal to 2 (P-P) cycles. Stability of the sinus rate is an important criterion for diagnosing type II block as a sudden increase in vagal tone can cause simultaneous sinus slowing and AV nodal block; this can superficially resemble type II second-degree AV block, which most observers feel is always infranodal. In type II block, the PR interval can be normal or prolonged, and the QRS complex can be narrow or wide. Typically, the PR interval is normal, and the QRS complex is wide because the block is in the His-Purkinje system. About 70% of cases of type II block are associated with bundle branch block, and 30% are associated with a narrow QRS complex and are therefore within the His bundle.^{3,8}

At the clinical level, the implications of Mobitz type II second-degree AV block are

quite different. Type I usually has a benign prognosis, is transient (reversible), seldom requires treatment, and does not necessarily indicate heart disease. It is often found in healthy, well-trained athletes and in healthy subjects. It may occur transiently in patients with acute inferior myocardial infarction or may be induced by drugs.⁹ In contrast to type I, type II is less common and implies more disease in the conducting system. It is usually associated with a defined cardiac disease process and is more likely to be permanent (irreversible). Since the site of the block is always below the AV node and usually below the bundle of His, escape rhythms are slow and the risk of progression to complete heart block is of concern. Permanent pacing is usually indicated to protect against symptomatic events such as syncope and thus protect the patient from injury. Prognosis in paced patients is primarily related to the underlying structural heart disease.^{10–12}

To summarize, this case illustrates an uncommon but important situation faced by medical directors. An apparently healthy, middle-aged applicant is discovered to have a relatively common, usually benign ECG abnormality. However, more in depth analysis of the ECG discloses additional ECG abnormalities that transform the assessment into a high-risk situation resulting in postponement of any offer of life insurance and necessitating immediate contact with the applicant and his attending physician.

REFERENCES

1. Martinez-Lopez JI. Semantics. *J La State Med Soc.* 1999;151:111–113.
2. Martinez-Lopez JI. A matter of degrees. *J La State Med Soc.* 1995;147:5–8.
3. Barold S, Hayes D. Second-degree atrioventricular block: a reappraisal. *Mayo Clin Proc.* 2001;76:44–57.
4. Martinez-Lopez JI. Brink of disaster. *J La State Med Soc.* 1997;149:259–262.
5. Martinez-Lopez JI. No bundle of joy. *J La State Med Soc.* 1998;150:47–49.
6. Upshaw C, Silverman M. The Wenckebach phenomenon: a salute and comment on the centennial of its original description. *Ann Intern Med.* 1999; 130:58–63.

7. Barold S, Lüderitz B. John Hay and the earliest description of type II second-degree atrioventricular block. *Am J Cardiol.* 2001;87:1433–1435.
8. Surawicz B, Uhley H, Borun R, et al. The quest for optimal electrocardiography, task force I: standardization of terminology and interpretation. *Am J Cardiol.* 1978;41:130–145.
9. Martinez-Lopez JI. What's in a name? *J LA State Med Soc.* 1997;149:47–49.
10. Shaw D, Kekwick C, Veale D, et al. Survival in second-degree atrioventricular block. *Br Heart J.* 1985; 53:587–593.
11. Strasberg B, Amat-Y-Leon F, Dhingra RC, et al. Natural history of chronic second-degree atrioventricular nodal block. *Circulation.* 1981;63:1043–1049.
12. Shaw D, Gowers J, Kekwick C, et al. Is Mobitz type I atrioventricular block benign in adults? *Heart.* 2004;90:169–174.