

## Chest X-ray Stages of Sarcoidosis

Joanne Mambretti, MD, FACP, FCCP

The initial chest x-ray is used to classify the stage of sarcoidosis. This report shows x-rays with findings of Stages I to IV. Underwriting sarcoidosis requires information of the history, the stage and pulmonary function tests.

**Address:** Prudential Financial,  
13001 County Road 10, Plymouth,  
MN 55442.

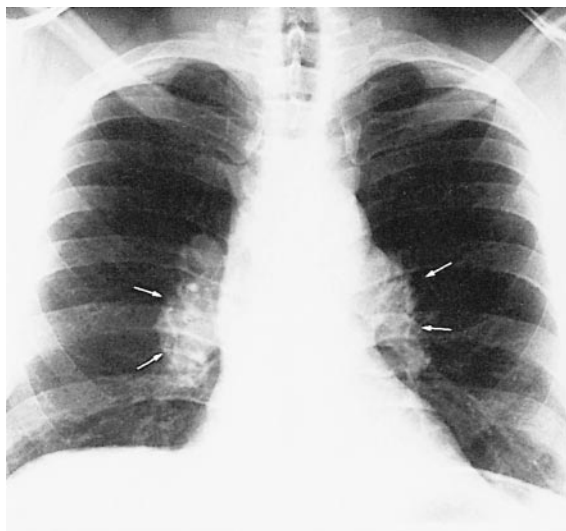
**Correspondent:** Joanne Mambretti,  
MD; Vice President, Medical Direc-  
tor.

**Key words:** Sarcoidosis, chest x-  
rays.

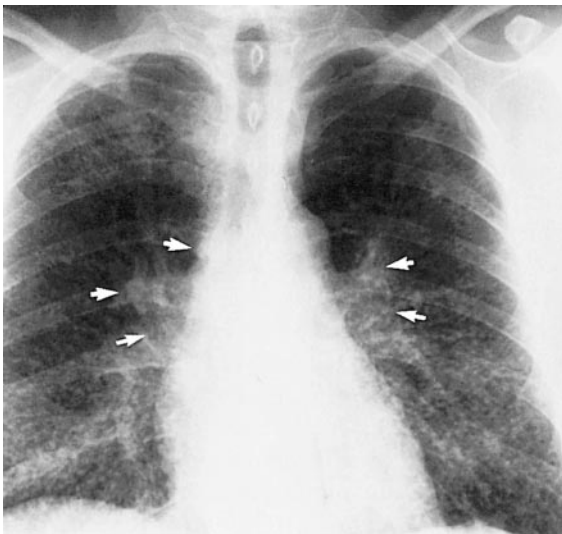Sarcoidosis can be discovered by a chest x-ray taken for another purpose in an asymptomatic patient. Symptomatic patients have chest x-rays as part of their workups. The initial chest x-ray is used to classify the stage of the sarcoidosis. Although there is no evidence to suggest that the stages progress from I to III, the stages offer a general prognosis. This series of chest x-rays are presented to show these stages of sarcoidosis. Diagnosis should never be made by chest x-ray alone as the differential includes lymphoma and tuberculosis, both of which can be asymptomatic.

Sarcoidosis is characterized by rounded microscopic, tumor-like masses of inflammatory cells primarily in the lungs or lymph nodes. It is a chronic disease of unknown cause. Patients may present with signs of cough, difficulty breathing, or skin lesions called erythema nodosa. Besides the lungs, lymph nodes and skin, sarcoidosis may involve the liver, spleen, salivary glands, eyes, heart and nervous system. Sarcoidosis most commonly affects individuals between the ages of 20 and 40 and affects men twice as often as women.

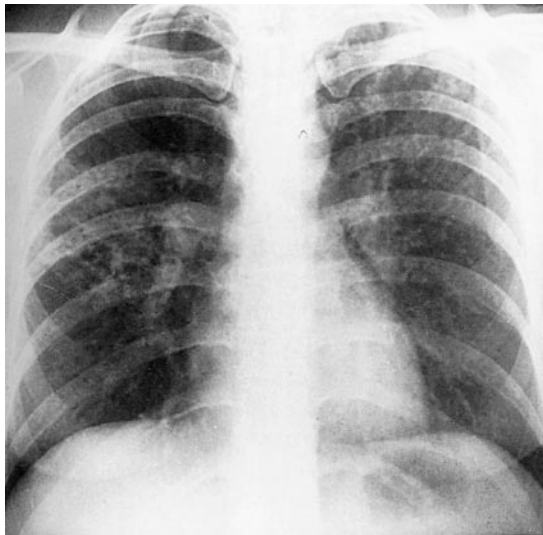
The diagnosis is suspected by history and chest x-ray findings and confirmed by microscopic findings of non-caseating granulomas in the lung. Transbronchial biopsy will establish the diagnosis in most of those with Stage II or III disease. If that biopsy is negative, a



**Figure 1.** Stage 1 sarcoidosis with bilateral hilar adenopathy. The lungs are normal. Reprinted from the *Fundamentals of Chest Radiology*<sup>1</sup> with permission from Elsevier.



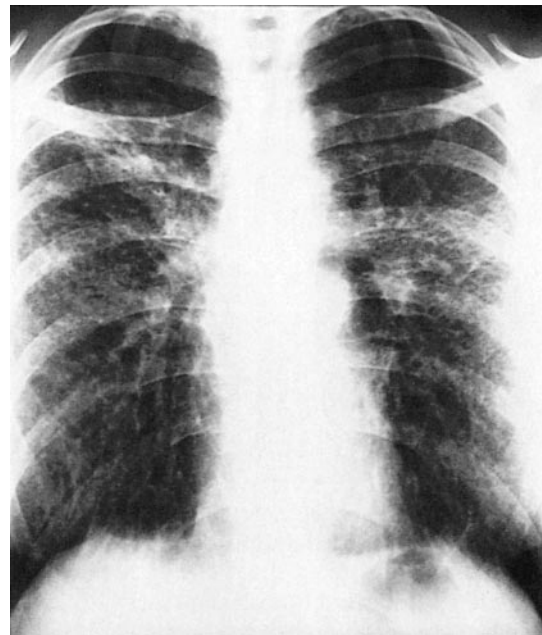
**Figure 2.** Stage 2 sarcoidosis with bilateral hilar and right paratracheal adenopathy and diffuse reticulonodular disease pattern in the lungs. The appearance is of fine lines and tiny nodules. Reprinted from the *Fundamentals of Chest Radiology*<sup>1</sup> with permission from Elsevier.



**Figure 3.** Stage 3 sarcoidosis with coarse reticulonodular pattern. There is no lymphadenopathy. Reprinted from the *Fundamentals of Chest Radiology*<sup>1</sup> with permission from Elsevier.

mediastinal node biopsy will establish the diagnosis in almost all of the patients.

After diagnosis, follow-up is done to monitor for resolution or progression of disease and for new organ involvement. All patients



**Figure 4.** Shows stage 4. There is diffuse reticulonodular pattern, the lung parenchyma is distorted by fibrosis, and the right hilum is retracted due to right upper lobe fibrosis. Reprinted from the *Fundamentals of Chest Radiology*<sup>1</sup> with permission from Elsevier.

are at risk for progression of lung involvement or involvement of other organs. Low dose corticosteroid is the standard therapy for symptomatic sarcoidosis, especially lung, heart, eye or CNS involvement. Because of the high rate of spontaneous remission, asymptomatic patients, even with positive x-rays, are not treated. The prognosis is good for most patients with the minority having progressive disease. Aggressive disease can result in extensive lung disease documented by chest x-ray and PFTs. The extent of loss of function is documented by pulmonary function tests, not by the appearance of the x-rays. In some cases with mild fibronodular pattern by chest x-ray, the PFTs will be normal.

## REFERENCE

1. Meholic A, Ketai L, Lofgren R. *Fundamentals of Chest Radiology*. Philadelphia, Pa: WB Saunders; 1996:120–121.