

*Interesting Electrocardiogram***CONGENITAL AV BLOCK**

M. IRENÉ FERRER, MD

Consultant in Cardiology

Metropolitan Life Insurance Company

Professor Emeritus of Clinical Medicine

College of Physicians and Surgeons, Columbia University

*Consultant Electrocardiographer*Presbyterian Hospital, Columbia Presbyterian Medical Center
New York, New York

The tracings on this 39-year-old applicant were sent to us by the applicant, who states his only symptoms are occasional "extra beats." The first electrocardiogram shows sinus rhythm at 88/min. with 2:1 AV block and a ventricular rate of 44. The second record was taken standing and just before the start of the treadmill exercise test. Mobitz II AV block and atrial pre-mature contractions are seen. The third record, done during treadmill exercise at a sinus rate of 130/min., shows no AV block or premature beats and the exercise test was negative. During the recovery phase of the treadmill test (tracing 4), with the heart rate of 107/min. indicating decreasing sympathetic tone, Wenckebach and Mobitz II periods (marked W and M) again appeared. An electrocardiogram in 1984 was unchanged and showed sinus rhythm with intermittent Wenckebach and Mobitz II forms of second degree AV block. A few atrial premature beats come and go in all tracings.

The evaluation of these tracings allows the diagnosis of congenital AV block since acquired high-grade AV block (second degree or complete AV block) does not show intermittency of the AV block over a 2-year period. This diagnosis is confirmed by the exercise test, which under the influence of increased sympathetic tone obliterates the AV block. This, of course, suggests that the site of the AV block is in the AV node.

Our concepts of congenital heart block have greatly altered in the past 15 years and the prognosis in most cases is very optimistic. Recent statistics from a large international cooperative study of congenital heart block indicate that 418 or 70% of the 599 cases were without associated lesions. This study also noted that most of the 8% mortality of these cases with no other heart disease occurred in the first year of life. In contrast to acquired chronic complete block where the blockage is distal to the common bundle of His and is due to bilateral bundle branch block, the location of the blockage in the congenital variety is generally proximal to the His bundle. This, of course, explains the almost invariably normal narrow QRS that characterizes the ventricular rhythm in congenital block, since it allows a healthy AV junctional or His bundle focus to develop the idioventricular rhythm. In the very rare instance

of an infra-His block in congenital heart block there is a much slower ventricular rate, a wide QRS, and a much poorer prognosis with an increased risk of sudden death.

The actual pathologic anatomy of congenital heart block is very variable and not simply a separation between atria and ventricles. Diminished or even absent connection between atrial myocardium and AV node may exist due to deficient development of the musculature of the peripheral portion of the atrial septum or upper ventricular septum. There may be basic malformations of the conduction system. The AV node itself may be normally developed or may be deficient, absent, or abnormal in shape. The His bundle may be absent, diseased, attenuated, or cut off from the AV node.

This wide variation in pathology—covering absence of structures all the way to deficiency in function of existing structures—accounts for a new finding in congenital heart block, namely, variation in the degree of completeness of the AV dissociation. Certain periods of high-degree but not complete AV block can be seen to occur, only to yield later to periods of complete block.

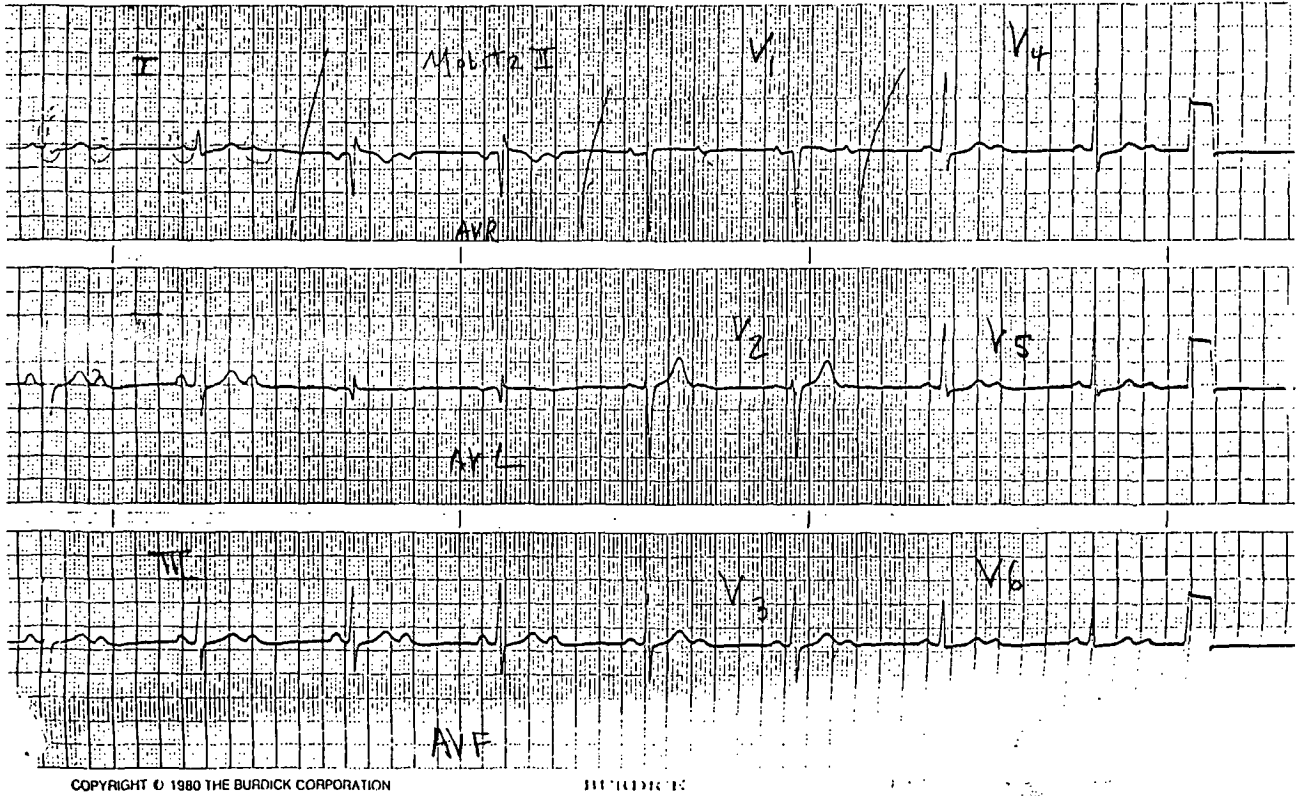
We now know that subjects with congenital AV block as the only anomaly—i.e., no other congenital cardiac defect—have an excellent prognosis and, from an insurance point of view, should not be highly rated since they appear to have a virtually normal life expectancy. Interestingly, the degree of AV block in such persons may vary from complete to a high degree of second degree AV block (both Mobitz II and Wenckebach types) and there may even be periods with only a long PR interval. Thus, detailed information is needed in such cases to arrive at a reasonable rating. In adults the ventricular rate in congenital complete block lies between 40 and 55/min. while in children it is around 70-80/min.—both rates reflecting the healthy intrinsic rhythmicity of His bundle tissue. The ventricular rate increase quite a lot with endogenous catecholamine stimulation, rising with exercise, fever, or pain, for example. This is rarely true of the idioventricular rhythm in acquired complete heart block. All these changes are best observed by Holter monitoring.

Rating for congenital AV block should, therefore, not be high. If detailed information, as herein, can be obtained a standard rating is possible.

REFERENCE

Ferrer MI. New Concepts in AV Block. *Trans Assoc Life Insur Med Dir Amer* (1980) 64:93-103.

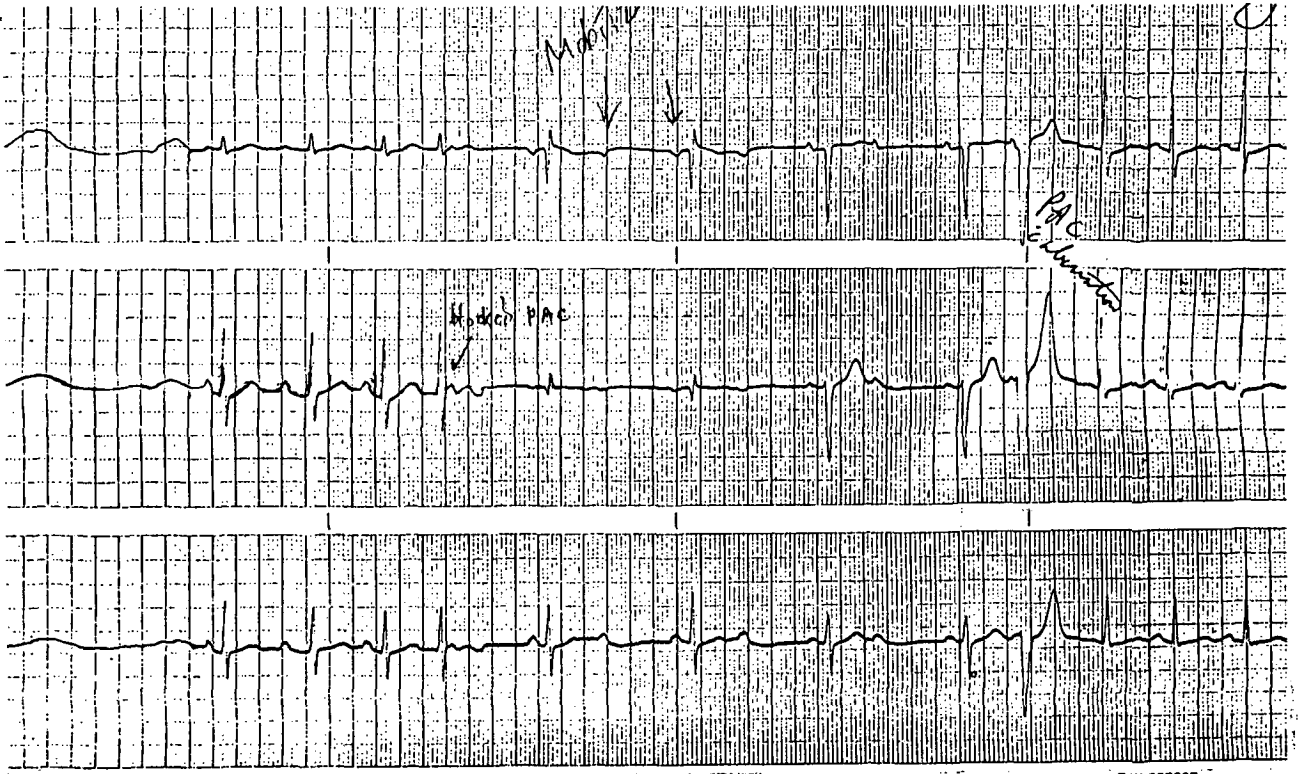
Tracing 1



COPYRIGHT © 1980 THE BURDICK CORPORATION

BURDICK

Tracing 2



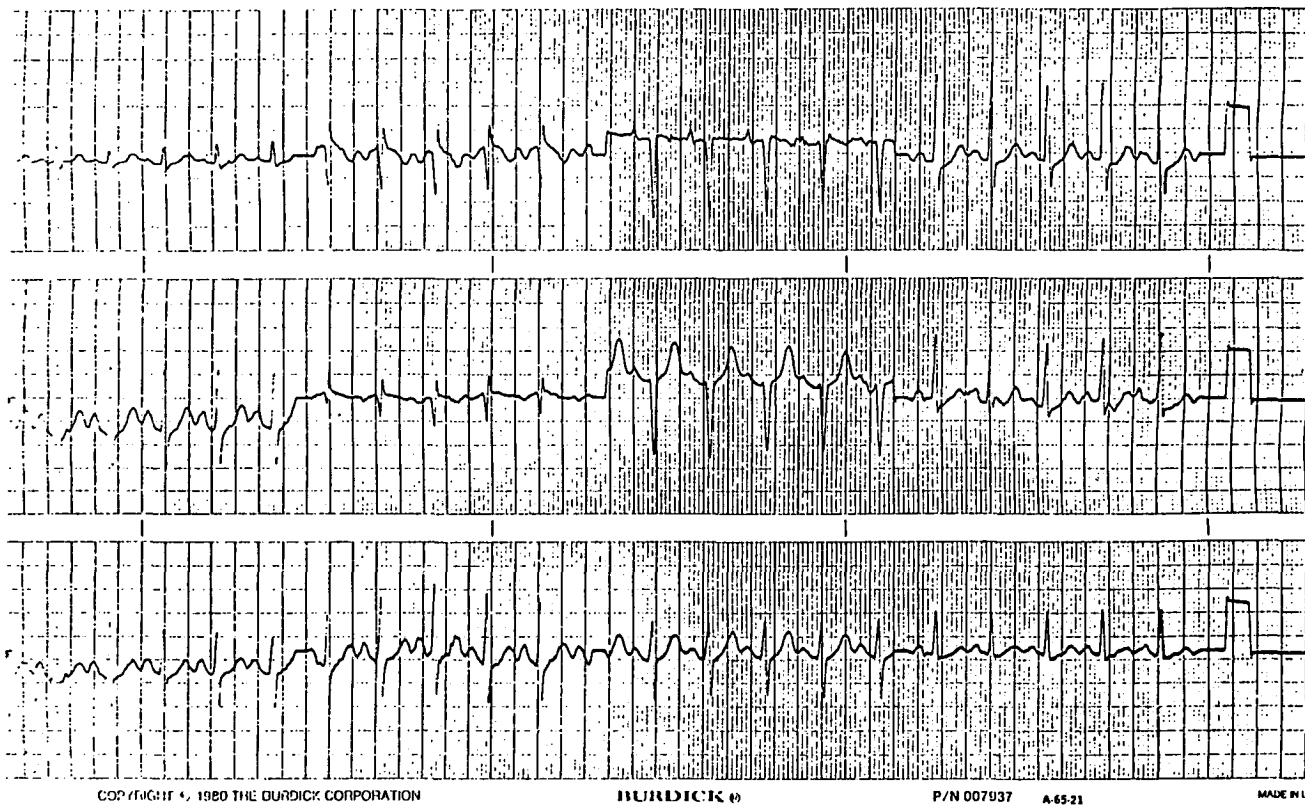
MADE IN USA

COPYRIGHT © 1980 THE BURDICK CORPORATION

BURDICK

P/N 007937 A-43-21

Tracing 3



Tracing 4

